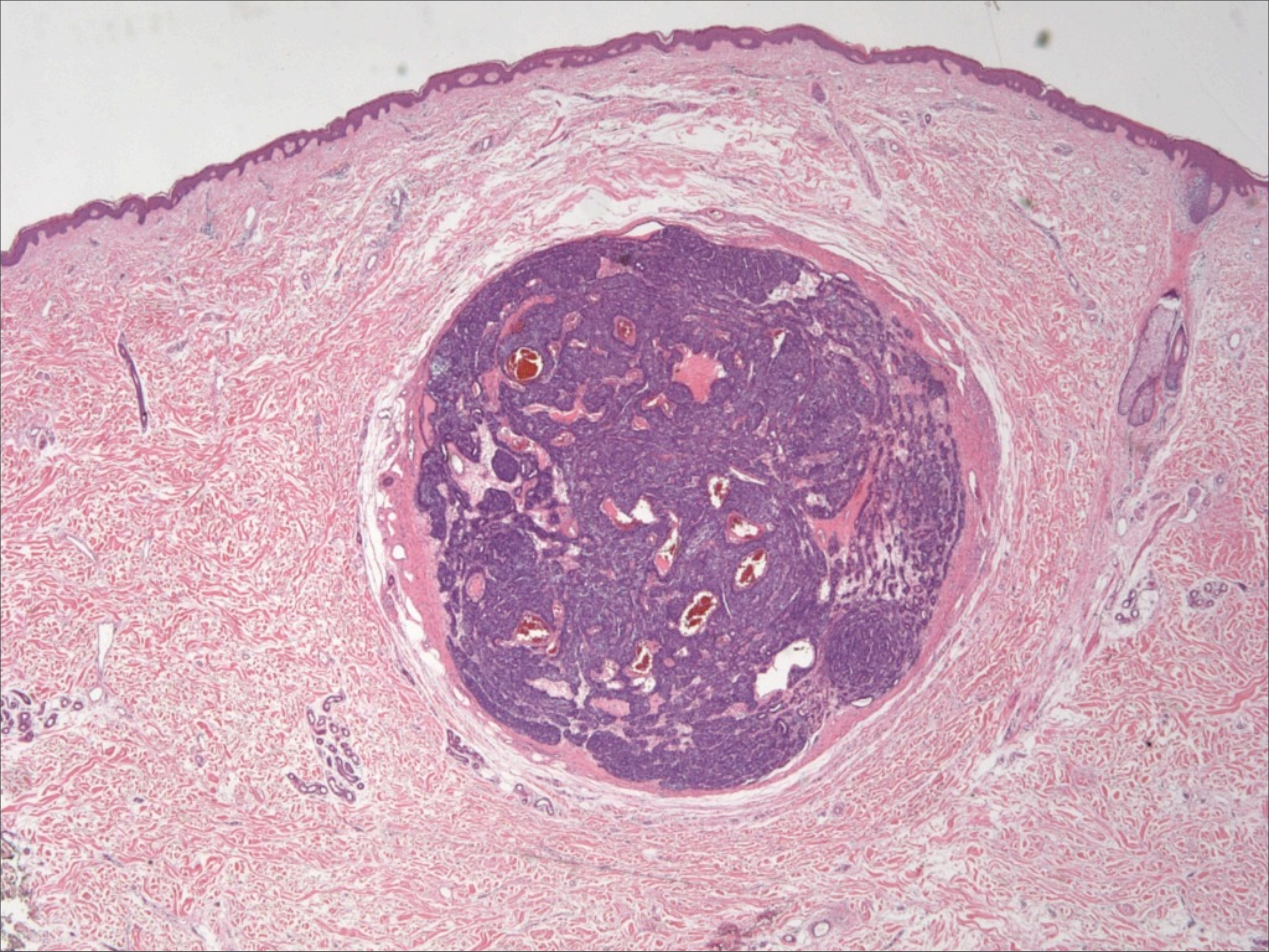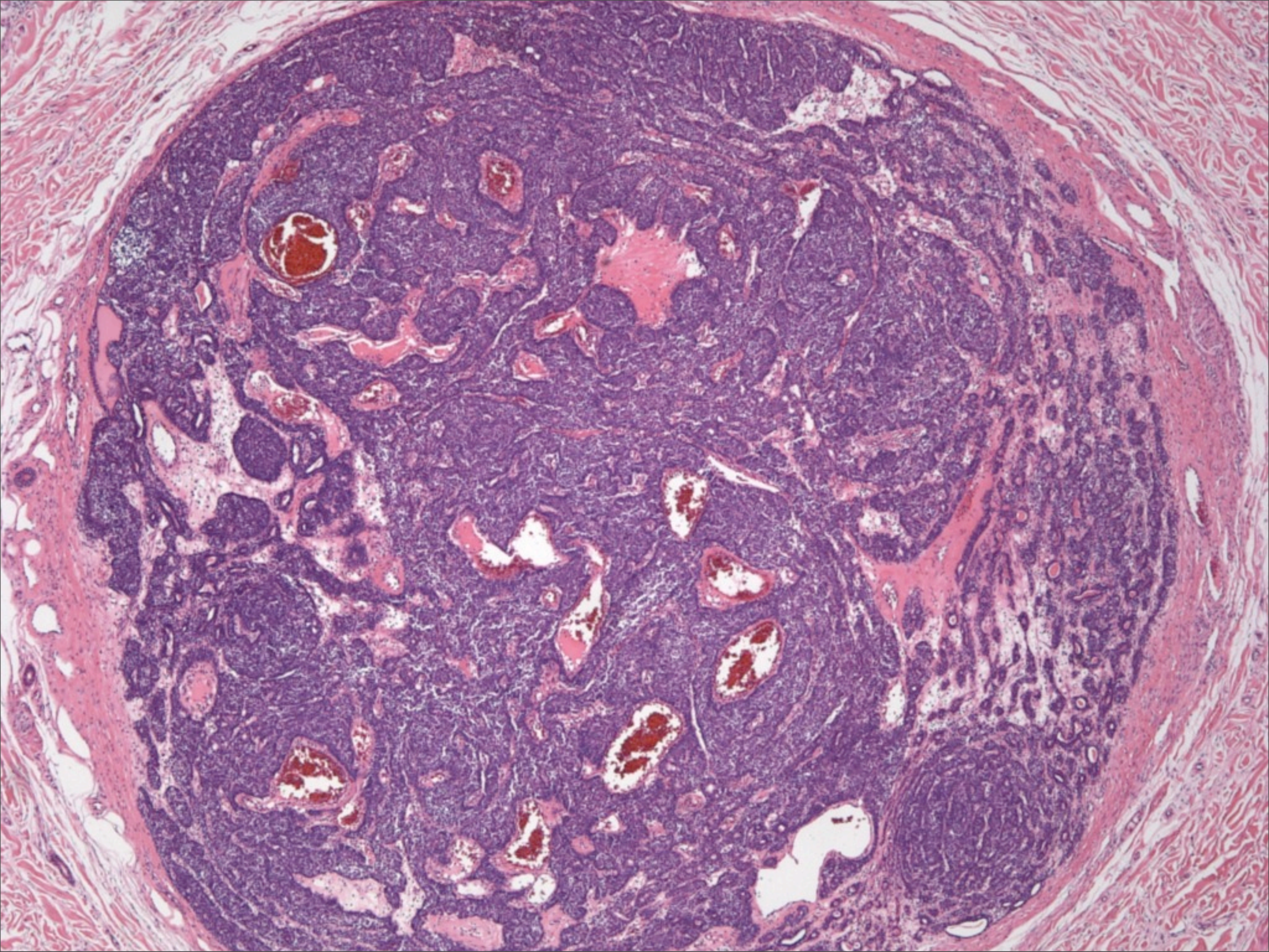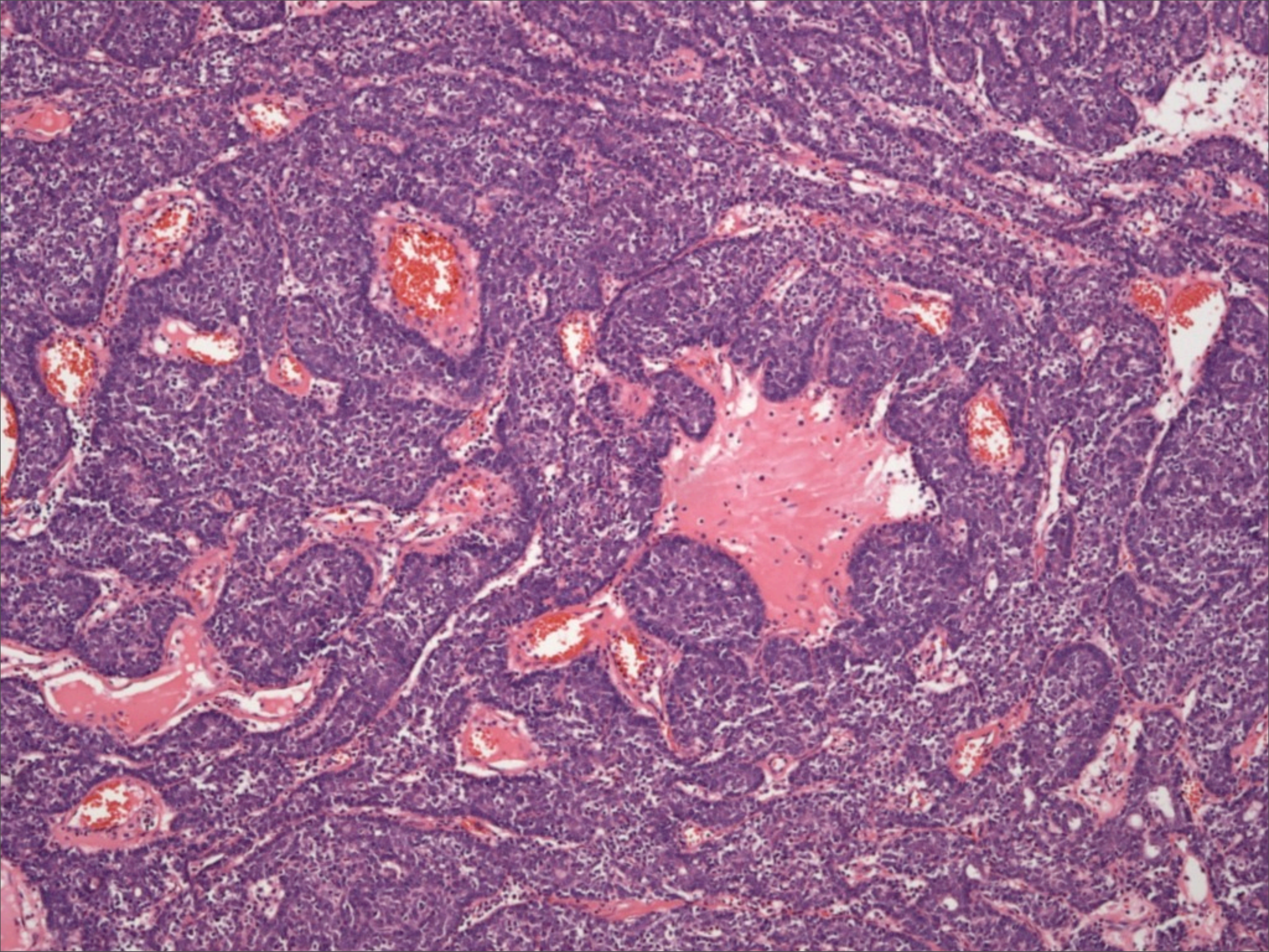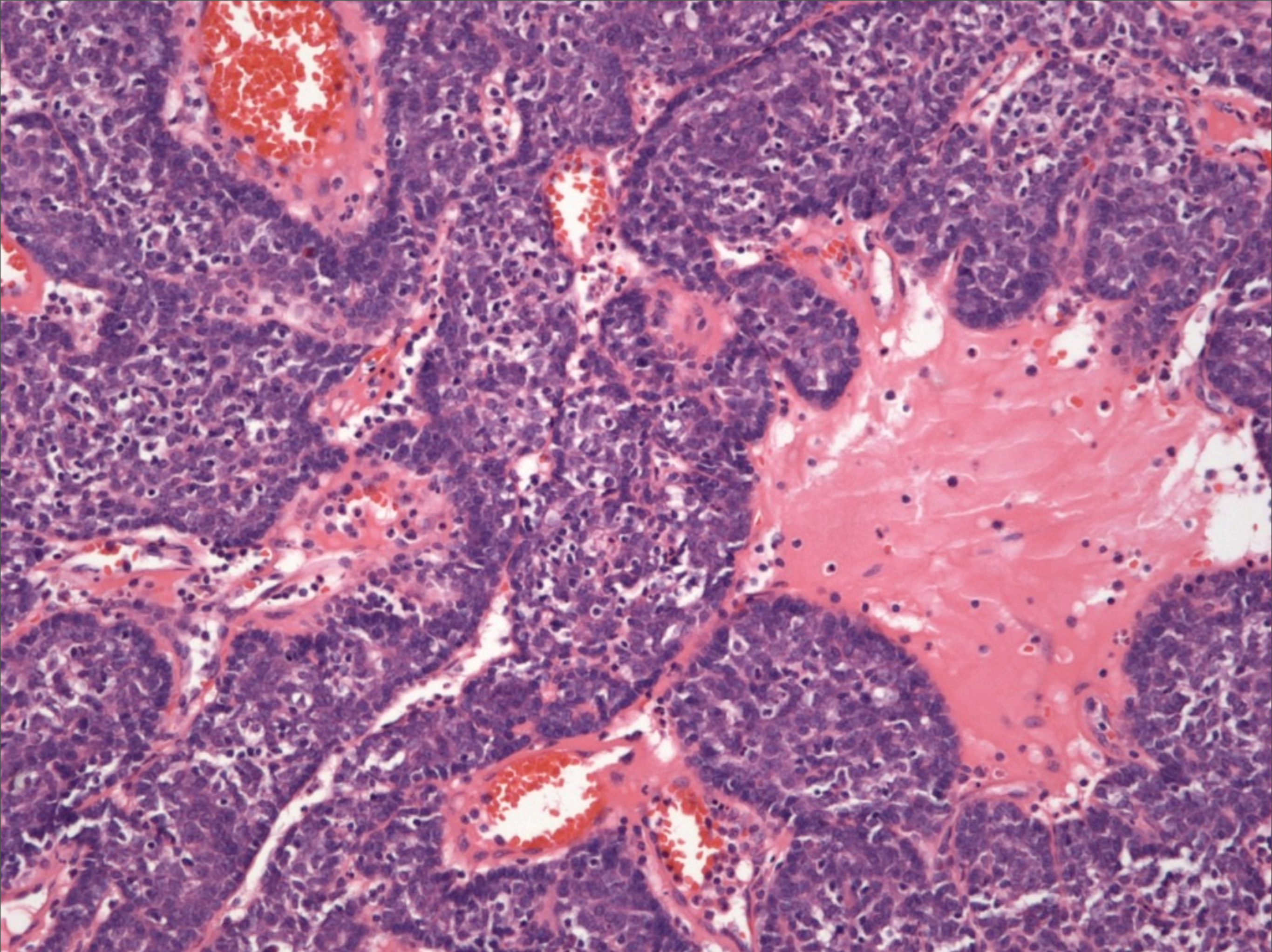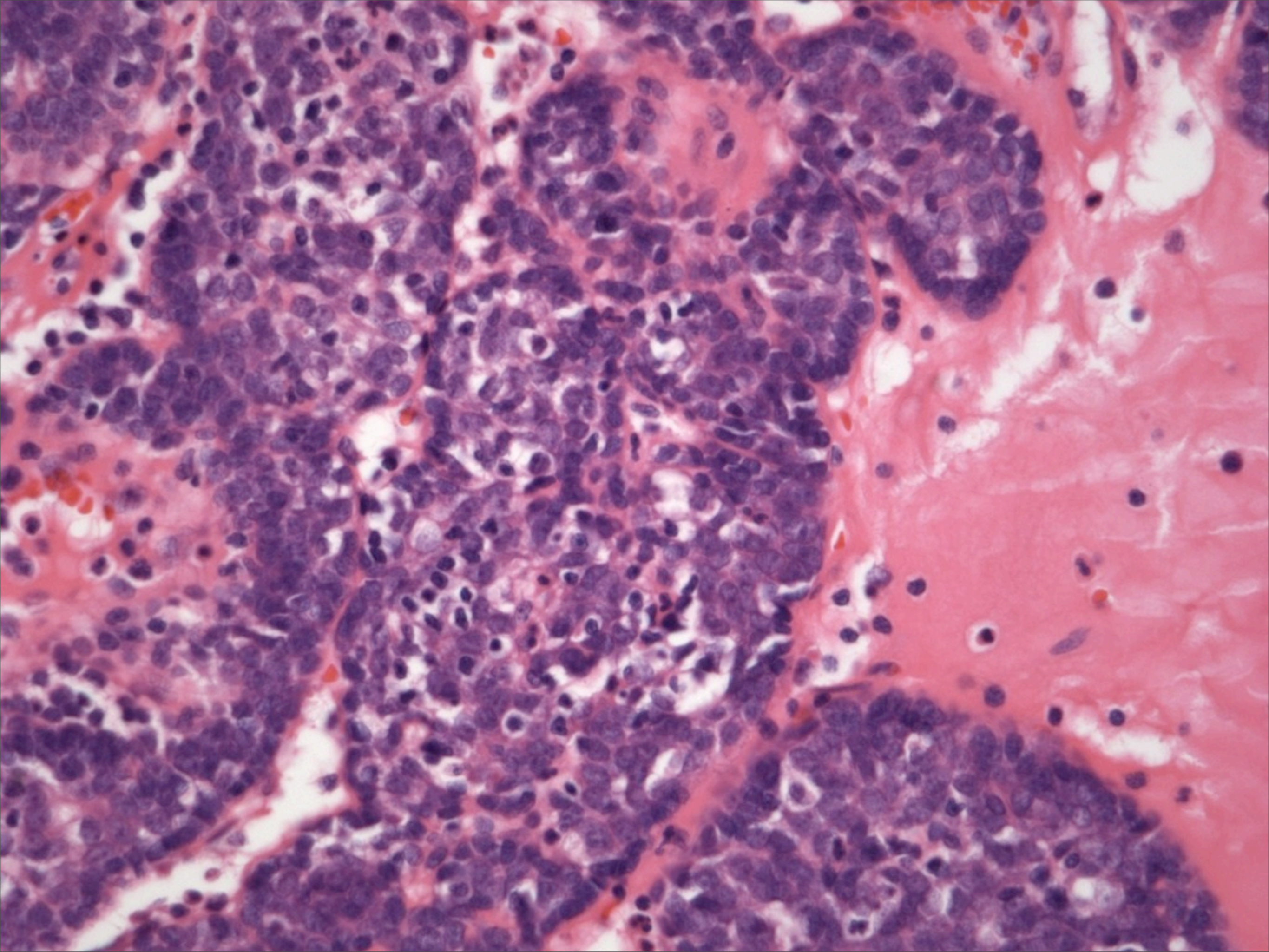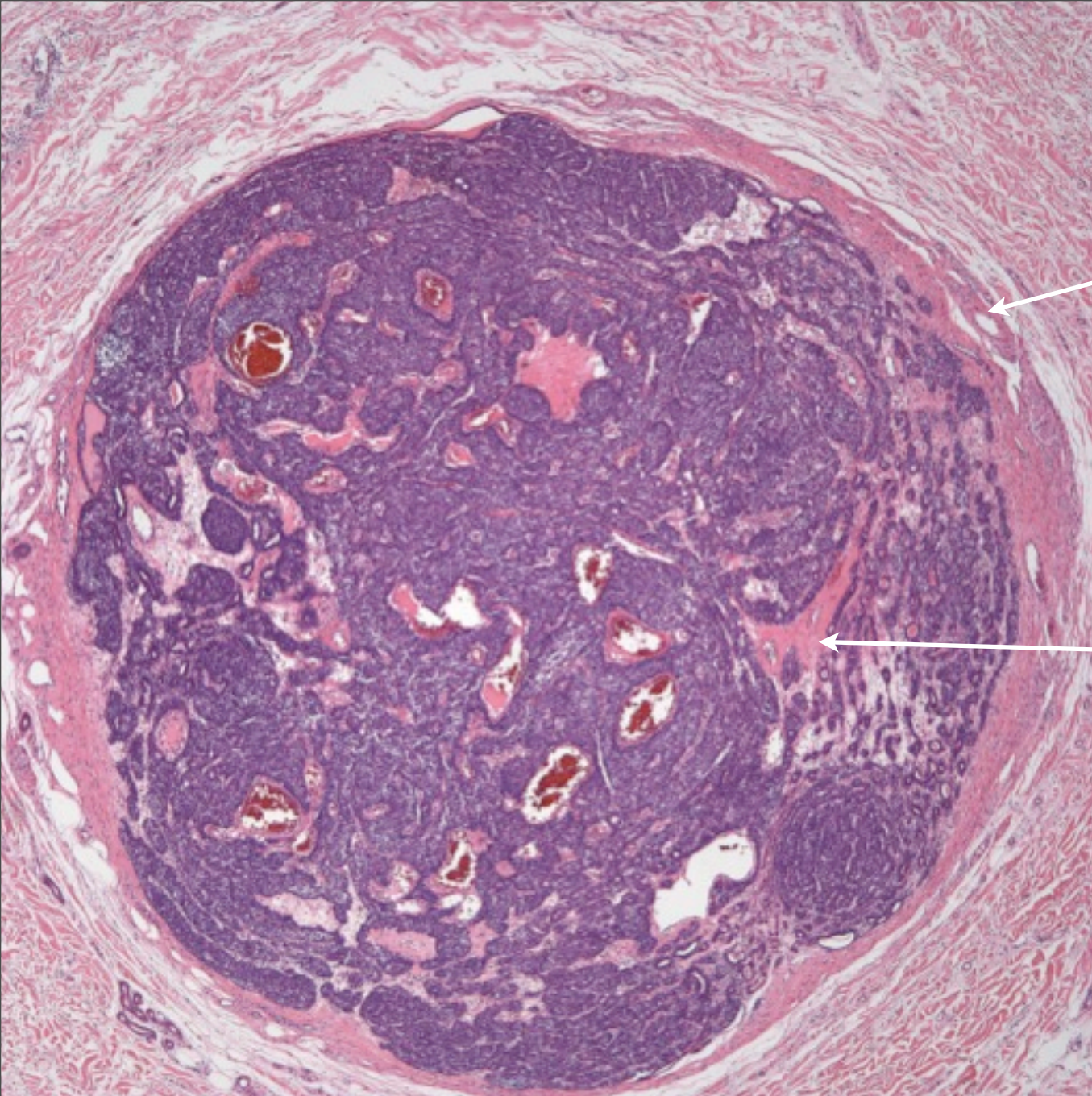


Eccrine Spiradenoma



Circumscribed dermal tumor

Increased hyalinized
basement membrane

Minimal cytologic atypia

Basaloid cells with increased thin-walled vessels